UpToDate® Official reprint from UpToDate®
www.uptodate.com © 2023 UpToDate, Inc. and/or its affiliates. All Rights Reserved.

Wolters Kluwer

Management of patent ductus arteriosus in term infants, children, and adults

Authors: Thomas Doyle, MD, Ann Kavanaugh-McHugh, MD, Jonathan Soslow, MD, Kevin Hill, MD
Section Editors: John K Triedman, MD, Heidi M Connolly, MD, FACC, FASE
Deputy Editor: Carrie Armsby, MD, MPH

All topics are updated as new evidence becomes available and our peer review process is complete.

Literature review current through: Feb 2023. | **This topic last updated:** Oct 26, 2022.

INTRODUCTION

The ductus arteriosus (DA) is a fetal vascular connection between the main pulmonary artery and the aorta (figure 1) that diverts blood away from the pulmonary bed. After delivery, the DA undergoes active constriction and eventual obliteration. A patent ductus arteriosus (PDA) occurs when the DA fails to close postnatally. (See "Physiologic transition from intrauterine to extrauterine life".)

The management of PDA in term infants, older children, and adults will be reviewed here. PDA in the premature infant and the pathogenesis, clinical manifestations, and diagnosis of PDA are discussed in separate topic reviews:

- (See "Patent ductus arteriosus in preterm infants: Pathophysiology, clinical manifestations, and diagnosis".)
- (See "Patent ductus arteriosus in preterm infants: Management".)
- (See "Clinical manifestations and diagnosis of patent ductus arteriosus in term infants, children, and adults".)

INDICATIONS FOR CLOSURE

In patients with a PDA, the primary management decision is whether to actively close the PDA or to conservatively observe and monitor the patient's cardiac status on a regular basis [1]. (See

'Management approach' below.)

PDA closure is **generally indicated** for patients with the following:

- **Moderate and large PDAs** – PDA closure is recommended for patients with moderate or large PDAs associated with symptoms of left-to-right shunting, clinical evidence of left-sided volume overload (ie, left atrial or ventricular enlargement), or reversible pulmonary arterial hypertension (PAH) [1]. Closure results in resolution of symptoms and a decrease in the likelihood or severity of PAH and the development of irreversible pulmonary vascular disease (Eisenmenger syndrome). (See "Clinical manifestations and diagnosis of patent ductus arteriosus in term infants, children, and adults", section on 'Moderate patent ductus arteriosus' and "Clinical manifestations and diagnosis of patent ductus arteriosus in term infants, children, and adults", section on 'Large patent ductus arteriosus'.)

- **Prior episode of endocarditis** – PDA closure is also indicated in patients with a previous episode of infective endocarditis (IE) regardless of the size of PDA in the absence of severe PAH. (See "Clinical manifestations and diagnosis of patent ductus arteriosus in term infants, children, and adults", section on 'Infective endocarditis'.)

The decision for PDA closure is **less clear** in patients with:

- **Small audible PDA** – We suggest closure of a small audible PDA even in the absence of clinically significant left-to-right shunting. We believe the long-term benefits of closure outweigh the risk of intervention [2-4]. Closure eliminates the potential complications of PDA, including IE, a rare but recognized complication of small PDA. An alternative approach is to defer closure and routinely follow the patient. (See "Clinical manifestations and diagnosis of patent ductus arteriosus in term infants, children, and adults", section on 'Small patent ductus arteriosus' and "Clinical manifestations and diagnosis of patent ductus arteriosus in term infants, children, and adults", section on 'Infective endocarditis'.)

  Due to technologic advancements (eg, transcatheter occlusion and video-assisted thoracoscopic surgery for PDA ligation), PDA closure can be accomplished with minimal risks in children. (See 'Transcatheter closure' below and 'Surgical ligation' below.)

  In adults with a small PDA, the American College of Cardiology/American Heart Association Task Force on Practice Guidelines suggests transcatheter occlusion as a reasonable option even in the absence of left heart volume overload [1]. If the PDA is left untreated, the patient should have routine follow-up every three to five years.

- **Small silent PDA** – The optimal management of the "silent ductus" (ie, no audible murmur) is uncertain. Most patients with small silent PDAs are managed with observation alone. However, some patients may reasonably opt for PDA closure, after reviewing the risks and theoretical benefits of the procedure. Until more data are available, we suggest that these decisions be individualized and based upon the values and preferences of the patient and family.

  The silent PDA is detected incidentally by imaging studies (usually echocardiography, magnetic resonance imaging, or computed tomography) performed for other indications. As the sensitivity of two-dimensional and Doppler echocardiography has improved, small PDAs are increasingly encountered as an incidental finding. Several studies have suggested that silent PDAs are present in 0.5 to 1 percent of the population [5,6], though this is likely to be an underestimate of the true prevalence.

  Silent PDAs do not have hemodynamic consequences, and, thus, the only impetus for closure is a theoretical increased risk of IE. (See "Clinical manifestations and diagnosis of patent ductus arteriosus in term infants, children, and adults", section on 'Infective endocarditis'.)

  However, while IE is a well-recognized complication associated with moderate and large PDAs, the risk of IE in patients with small silent PDAs is unknown and is likely very small. The available data supporting a theoretical increased risk of IE in this population are limited to a handful of individual case reports [7-10]. In a retrospective report of 106 children with small (<1.5 mm diameter) silent PDAs managed at a single center from 2005 through 2009, 81 percent were managed with observation alone and 19 percent underwent transcatheter closure [11]. There were no cases of IE in either group over follow-up of 6 to 54 months.

  Given how common small silent PDAs are in the general population and the apparent rarity of IE in this population, many experts believe routine closure is not warranted [5,11-13]. However, other experts continue to advocate for closure of silent PDAs to prevent IE [4].

PDA closure is **not advised** in patients with:

- **Severe PAH** – In patients with severe and irreversible PAH, procedural risks associated with PDA closure are considerably higher than in patients without severe PAH. In addition, PDA closure does not appear to improve survival, and right-to-left ductal shunting may be necessary to maintain cardiac output during episodes of increasing pulmonary vascular resistance [1,14]. (See 'Patients with pulmonary arterial hypertension' below and

"Pulmonary hypertension in adults with congenital heart disease: General management and prognosis".)

MANAGEMENT APPROACH

Observation versus patent ductus arteriosus closure — The two approaches for managing patients with PDA are observation and elective ductal closure. Management decisions are dependent upon the size of the left-to-right shunt, the age and size of the patient, and the family's choice regarding the benefits (ie, prevention of long-term complications associated with PDA) versus the risks of intervention. (See 'Indications for closure' above.)

- **Observation** – If elective closure is deferred, antibiotic prophylaxis is not necessary for medical or dental procedures. Patients need to be evaluated on a regular basis to monitor for signs of increased cardiac workload and/or pulmonary vascular changes. If these occur, PDA closure is recommended. (See "Clinical manifestations and diagnosis of patent ductus arteriosus in term infants, children, and adults", section on 'Infective endocarditis' and 'Indications for closure' above.)

- **PDA closure** – Once the decision is made to proceed with PDA closure, the choice of therapeutic interventions is dependent upon the size and age of the patient, the size and morphology of the PDA, and the degree of shunting and symptomatology.

Given the number of factors affecting the therapeutic choice for PDA closure, it is difficult to provide a simplified algorithm for management. Nonetheless, generalizations can be made to help simplify treatment decisions. In the following sections, the choice of treatment is based upon the age and size of the patient.

Premature infants — In preterm infants, inhibitors of prostaglandin synthesis, such as indomethacin and ibuprofen, are typically the initial interventions for PDA closure, though surgical ligation is sometimes necessary, and transcatheter device closure has been used at specialized centers. The management of PDA in premature infants is discussed in greater detail separately. (See "Patent ductus arteriosus in preterm infants: Management".)

Term infants <6 kg — In term neonates and older infants, inhibitors of prostaglandin synthesis (ie, indomethacin and ibuprofen) are not effective for PDA closure and thus are not recommended. We suggest delaying closure if possible in infants <6 kg since the risk of complications with transcatheter closure appears to be greater compared with larger infants and children [15-18]. At our institutions, we approach PDA management based upon symptoms as follows:

- **Asymptomatic** – Infants without heart failure are observed with frequent monitoring of their cardiorespiratory status and growth until they are large enough to undergo transcatheter closure. If cardiorespiratory symptoms or growth impairment develop, medical management is initiated as described in the following section.

- **Symptomatic** – In infants with large PDAs and symptomatic left-to-right shunting that results in heart failure (eg, poor feeding, failure to thrive, respiratory distress, and sweating), medical management is initiated with digoxin and furosemide. (See "Heart failure in children: Management".)

  If medical management fails, closure of the ductus is warranted. Options for closure include surgical ligation or transcatheter closure in select cases if ductal anatomy is favorable. (See 'Surgical ligation' below and 'Transcatheter closure' below.)

  Studies directly comparing surgical ligation with transcatheter closure in infants <6 kg are lacking. In a report from the Improving Pediatric and Adult Congenital Treatments (IMPACT) registry that included data on 747 infants <6 kg who underwent transcatheter PDA closure, the procedure was successful in 94.7 percent; however, the rate of major adverse events was 12.6 percent, which is 5- to 10-fold higher than in children >6 kg [16]. Similar success and adverse event rates were noted in a multicenter study from the United Kingdom [17]. In a meta-analysis of 38 uncontrolled studies evaluating transcatheter PDA closure in 635 infants <1 year old, the pooled success rate was 92.2 percent; 76.7 percent had immediate ductal occlusion, and the majority closed within 24 hours [15]. However, the adverse event rate was 23.3 percent, including 13 major or catastrophic events, 12 of which occurred in infants <6 kg.

  These data suggest that the risk of complications in transcatheter PDA closure in infants <6 kg is higher than in larger infants and children. Thus, when choosing between a transcatheter versus surgical approach in an infant this size, clinicians should carefully weigh the individual risks and benefits, including consideration of ductal morphology, patient comorbidities, institutional expertise, and parental preferences.

Infants and children >6 kg — Transcatheter occlusion (image 1) is generally preferred over surgical ligation in infants and children who weigh ≥6 kg because it is less invasive, does not result in a surgical scar, and is at least as cost-effective, if not less costly [12,19-21]. (See 'Transcatheter closure' below.)

Because of the limitations of transcatheter closure in the small child, transcatheter closure may not be feasible or offered at all centers. For patients without access to a center with expertise in transcatheter closure, surgical ligation is a safe and effective option. Video-assisted thorascopic

surgery for PDA ligation is minimally invasive and can be safely performed in children of this size and age range. (See 'Surgical ligation' below.)

Inhibitors of prostaglandin synthesis (ie, indomethacin and ibuprofen) are ineffective in children and should **not** be used. (See 'Pharmacologic therapy' below.)

Adolescents and adults — In adolescents and adults, transcatheter occlusion is the preferred intervention for PDA closure [20]. In patients with small PDAs, coil occlusion can be used; for moderate to large PDAs, either coil or device occlusion can be used [1]. (See 'Transcatheter closure' below.)

Given the complexities and associated risk of complication with transcatheter occlusion of very large PDAs (>14 mm), some centers opt for surgical ligation in this setting. In addition, surgical ligation is indicated in patients with distorted ductal morphology due to aneurysm or endarteritis that precludes device closure [1]. (See 'Surgical ligation' below.)

Patients with pulmonary arterial hypertension — Decisions regarding PDA closure in patients with pulmonary arterial hypertension (PAH) should be individualized with careful consideration of the risks and benefits. It is difficult to predict which patients with PAH will benefit from PDA occlusion. Reported favorable features include [22,23]:

- Lower baseline pulmonary vascular resistance
- Lower pulmonary arterial pressures
- Baseline left-to-right shunt with Qp:Qs ratio of >1.5, and
- Tolerance of PDA test occlusion including a pulmonary arterial to systemic arterial pressure ratio <0.5

By contrast, patients with severe PAH (defined as a pulmonary vascular resistance >6 Wood units x m^2 when breathing 100 percent oxygen) usually are not considered suitable candidates for PDA closure because they generally have a high risk of procedural complications or mortality, and often have progressive pulmonary vascular disease despite PDA closure [14]. In addition, PDA closure is not recommended for patients with severe PAH that has resulted in a right-to-left shunt (ie, Eisenmenger syndrome) because they depend on the shunt to avoid heart failure and maintain cardiac output. Medical management of patients with Eisenmenger syndrome is discussed separately. (See "Pulmonary hypertension in adults with congenital heart disease: General management and prognosis".)

In select patients with reactive PAH, transcatheter PDA closure may be feasible. In a case series of 137 adult and adolescent patients with PDA and severe PAH (baseline catheterization-measured pulmonary artery pressure ≥45 mmHg) who underwent trial PDA occlusion in the

catheterization laboratory, 98 percent tolerated the trial (ie, demonstrated stable hemodynamics during PDA occlusion) and proceeded to successful PDA device closure [23]. At a median follow-up of five years (range 1 to 10 years), 13 percent of patients demonstrated echocardiographic evidence of residual severe pulmonary hypertension (mean estimated right ventricle systolic pressures of 86 mmHg), and five patients received drug therapy for PAH. Pre-PDA trial occlusion, systolic pulmonary arterial to systemic arterial pressure ratio >0.5 was a strong predictor of postclosure residual pulmonary hypertension. Importantly, there were no deaths among the patients who underwent PDA closure.

In a similar report of 29 adults (mean age 31.1, range 18 to 58 years) with PDAs and PAH (mean pulmonary vascular resistance 9.1 Wood units), 20 patients underwent successful PDA occlusion after demonstrating PAH reversibility during temporary PDA occlusion [22]. Short-term follow-up (three to six months after PDA occlusion) demonstrated improvement in symptomatology and decreases in the sizes of the left atrium, left ventricular diastolic dimension, and pulmonary artery. Notably, an editorial accompanying this report raised concerns about such a strategy because of the potential of long-term morbidity and mortality associated with the removal of a potential right-to-left shunt, which may be needed to maintain cardiac output during episodes of increasing pulmonary vascular resistance due to progressive pulmonary vascular changes [14].

THERAPEUTIC INTERVENTIONS

Interventions for PDA closure include:

- Pharmacologic therapy, which is used exclusively in premature infants
- Transcatheter catheter occlusion
- Surgical ligation

The details of these interventions are described in the following sections. Management decisions regarding whether to close the PDA and, if so, which intervention to choose are reviewed in the previous discussion. (See 'Indications for closure' above and 'Management approach' above.)

Pharmacologic therapy — In preterm infants, inhibitors of prostaglandin synthesis, such as indomethacin and ibuprofen, are used as the initial interventions for PDA closure. However, these agents are ineffective in term infants and older patients with a PDA and should not be used. Their lack of efficacy in term infants and older patients is probably due to histologic differences between the ductus of a premature and a term infant. Pharmacologic therapy for

PDA closure in the premature infant is discussed separately. (See "Patent ductus arteriosus in preterm infants: Management", section on 'Nonselective cyclooxygenase inhibitors'.)

Transcatheter closure — Transcatheter PDA occlusion was first introduced in 1967 and provides a safe alternative to surgical ligation [24,25]. Access is generally achieved through the femoral artery or vein. Patients usually are fully recovered after the procedure and can be discharged the same day or after an overnight observation.

Although a variety of techniques have been developed, coils (picture 1) or occlusion devices (picture 2A and picture 2B) are the two most commonly used, both of which allow successful PDA occlusion with normalization of left ventricular hemodynamics [26,27].

Occluder choice — The choice of occluder (coil versus the various devices) is dependent upon ductal morphology and size and the age/size of the patient.

In a multicenter case series of 496 PDA closures, device occluders were used in two-thirds and coils in the remaining one-third [27]. A device was used more frequently in younger patients (ie, <3 years of age), patients <11 kg, and patients with a PDA diameter >1.5 mm. There was institutional variation, with three of the eight centers preferentially using a device for PDAs with a diameter >1.5 mm. In this cohort, adverse events were more common in coil procedures (10 versus 2 percent).

Device occlusion — Several devices are available for transcatheter PDA closure [28-30]. Many of the earlier devices had unacceptably high rates of residual shunt or were cumbersome to use when applying to a moderate or large PDA [31]. Newer devices have been developed with design improvements that have resulted in greater safety and efficacy. These include:

- **Amplatzer ductal occluder** – The Amplatzer ductal occluder (ADO) is the most commonly used device (picture 2A and image 1). It was approved by the US Food and Drug Administration (FDA) in 2003 for PDA occlusion in children ≥6 months and ≥6 kg [32-34]. It is not used in infants <6 months old and those weighing <6 kg, as the risk of major adverse events and failure of the device is high in these patients [35]. In addition, the ductal ampulla must be able to accommodate the aortic retention disk. If the child's vasculature is too small to accommodate the disk, or if the disk is improperly situated, it can cause coarctation of the aorta.

  The ADO device is a top-hat shaped, repositionable plug occluder made of nitinol wire mesh, which is delivered through a 5F to 7F long sheath [36]. A retention skirt extends radially around the distal part of the device and is positioned in the aortic ampulla,

assuring secure fixation in the mouth of the PDA. Polyester fabric, which is sewn into the occluder, induces thrombosis that closes the communication.

In two large case series (including a total of 689 patients, ranging in age from 0.2 to 70.7 years), the ADO was successfully implanted in >90 percent of procedures [31,33]. Complete closure of the PDA without residual shunt was noted in 44 to 76 percent of patients immediately following the procedure, and this rate increased to 66 to 88 percent at 24 hours and 97 percent at one month following the procedure. In the smaller of the two series, patients were followed for one year and all but one patient maintained complete occlusion [33]. Complications in the two series included one death (0.1 percent), five cases of device embolization (0.7 percent), two cases of partial left pulmonary artery obstruction (0.3 percent), and one case of mild aortic narrowing (0.1 percent).

- **ADO II** – The ADO II device (picture 2B) was approved by the FDA in 2013 for use in children ≥6 months and ≥6 kg [37]. The device differs from the earlier ADO version as it has a central waist with retention disks on either side. In addition, it comes in two different lengths, does not contain embedded fabric, and can be deployed through a 4 or 5 Fr delivery catheter.

  In a prospective study of 192 patients (age range from 6 months to <18 years) with a PDA diameter ≤5.5 mm who were enrolled at 25 sites in the United States, the technical success rate was 92.7 percent [38]. There were two device-related serious adverse events, including one device embolization and one residual shunt requiring closure. Overall, 98.2 percent of patients with available data had no residual shunt at six-month follow-up.

- **PFM Nit-Occlud device** – The PFM Nit-Occlud device received FDA approval in 2013 for use in children ≥5 kg [39]. The device consists of a cone-in-cone series of coils with the widest diameter on the intended aortic end, a central narrowing, and a smaller diameter on the intended pulmonary artery end.

  In a prospective study of 357 children (ages 6 months to 18 years) with PDA diameter <4 mm who were enrolled at 15 centers, implantation of the PFM Nit-Occlud device was successful in 97 percent [40]. Of the 309 patients with data at 12 months, complete closure was noted in 97 percent. There were five major device-related adverse events reported (1.4 percent), including embolization (n = 2), device retrieval (n = 2), and aortic obstruction (n = 1).

- **Amplatzer vascular plug II** – The Amplatzer vascular plug II (AVPII) was approved by the FDA in 2007. It is a finely woven nitinol mesh consisting of two flat discs on either side of cylindrical plug. The central plug and the discs are of the same diameter. In a retrospective

single center study, the APVII was shown to be effective in closing all PDA shapes with an 89 percent angiographic closure rate and a 100 percent closure rate by echo the following day [41].

- **Amplatzer piccolo occluder** – The Amplatzer piccolo occluder is a device that can be used in both term and preterm infants. It was approved by the FDA in 2019 for use in infants >700 g and >3 days old [42]. This device is discussed separately. (See "Patent ductus arteriosus in preterm infants: Management", section on 'Percutaneous transcatheter occlusion'.)

Coil occlusion — A variety of deployment methods have been used to achieve complete and permanent occlusion by optimal coil positioning across the PDA (picture 1) [43,44]. Numerous studies have documented the safety and efficacy of coil occlusion for small PDAs (<3 mm in diameter) [45]. However, the likelihood of an unfavorable outcome (eg, coil embolization and residual shunt) rises with increasing ductal size [46].

Although residual shunts are sometimes present immediately following coil occlusion, these shunts typically resolve after a few months [45,47]. Outcomes using coils for occlusion may be suboptimal in cases with a window-like or tubular ductal morphology, or moderate to large PDA [45]. Although several techniques have been developed, including the use of large diameter (0.052 inch) coils and multiple coils delivered simultaneously [48,49], coil occlusion of the moderate to large PDA is more complicated, requires longer fluoroscopy time, and has higher rates of embolization and residual shunts compared with device occluders [45,50].

Magnetic resonance imaging (MRI)-compatible coils are the coil of choice for PDA occlusion and these have replaced the stainless steel coils were used initially. (See 'Magnetic resonance imaging compatibility' below.)

Efficacy and complications related to coil occlusion were illustrated in a large case series from the European Paediatric Cardiology Registry including 1291 attempted PDA coil occlusions in 1258 patients (median age 4 years; range 0.1 to 52 years) [45]. Occlusion was achieved immediately in 59 percent of patients and rose to 95 percent one year after the procedure. Unfavorable outcomes occurred in 10 percent of cases, including failure to implant (4.2 percent), coil embolization (3.8 percent), residual leak requiring further intervention (1 percent), persistent hemolysis (1 percent), duct recanalization (3 patients), and flow impairment to adjacent structures (2 patients). Larger PDA size was associated with increased risk of an unfavorable outcome. PDAs that were tubular in shape were also more likely to be associated with an unfavorable outcome. (See "Clinical manifestations and diagnosis of patent ductus arteriosus in term infants, children, and adults", section on 'Ductal embryology and anatomy'.)

Magnetic resonance imaging compatibility — MRI-compatible coils are the coil of choice for PDA occlusion; however, stainless steel coils were used initially and may be affected by the MRI field. This should be taken into account when considering MRI in a patient with a PDA coil.

The Amplatzer ductal occluders (ADO I and II) and the PFM Nit-Occlud devices are considered to be MRI-compatible and safe, provided the following MRI limits are used:

- Static magnetic field of 3T or less
- Spatial gradient magnetic field of 720 G/cm or less
- Maximum MRI system-reported, whole-body-averaged specific absorption rate (SAR) of 2W/kg (up to 3W/kg for the ADO devices) for 15 minutes of scanning

Image quality may be distorted in the area of the coils and devices.

Surgical ligation

Technique — Technical expertise gained since the time of the first successful surgical PDA ligation in 1939 allows this procedure to be performed safely even in extremely low birth weight infants (birth weight <1000 g).

The surgical approach and technique are dependent upon the size and age of the patient:

- **Preterm infants** – Surgical ligation in premature infants is discussed separately. (See "Patent ductus arteriosus in preterm infants: Management", section on 'Surgical ligation'.)

- **Term infants and children** – In term infants and older children, surgical ligation can be performed with thoracotomy or using video-assisted thoracoscopic surgery (VATS):

  - **Thoracotomy** – The surgical approach is with a posterolateral thoracotomy, similar as in preterm infants. The incision is through the third left intercostal space in infants and the fourth left intercostal space in older patients. Many surgeons prefer multiple ligations or division to minimize the risk of recurrent shunt [51].

  - **VATS** – VATS for PDA ligation can be a safe and effective procedure for PDA closure, and is less invasive than standard thoracotomy surgical closure [52]. It involves isolation of the PDA using thoracoscopic techniques and interruption of the PDA by placement of a surgical clip. Reported contraindications to VATS ligation include ductal diameter >9 mm, previous thoracotomy, ductal calcifications, active infection, and ductal aneurysm [53].

Data directly comparing VATS and thoracotomy are limited, and it is unclear from these studies which technique has a lower complication rate [54,55]. In a large retrospective review of 1300 patients who underwent VATS ligation, 3 patients had residual shunts at follow-up, 12 patients had transient recurrent laryngeal nerve injury (with only one having persistent vocal cord dysfunction), and 7 patients required conversion to a thoracotomy [56]. There were no mortalities. In a subsequent review of 2000 patients, the same group noted similar results and reported that esophageal auscultation could be used to assess residual patency [53].

- **Adults** – In the majority of adult patients, transcatheter occlusion is the treatment of choice (see 'Transcatheter closure' above); however, surgical closure may be needed when the ductal anatomy precludes device or coil closure (ie, large ductus, aneurysms, or infection) [1,57]. In these cases, surgical closure by thoracotomy or sternotomy, with or without cardiopulmonary bypass, is performed.

Complications — Reported complications after surgical PDA ligation include [54,55,58]:

- Recurrent laryngeal nerve paralysis
- Respiratory compromise
- Infection
- Pleural effusion/chylothorax
- Pneumothorax
- Bleeding
- Scoliosis (more likely after thoracotomy)
- Residual ductal patency

Comparison between approaches — Based on the available data, both surgical ligation and transcatheter closure appear to have high success rates and low complication rates [21]. Transcatheter closure is associated with a shorter duration of hospitalization, which likely translates into lower costs; however, the trade-off is a higher likelihood of residual shunt requiring reintervention (which, if necessary, generally consists of a second transcatheter procedure).

In a meta-analysis comparing success rates and associated complications of PDA closure by surgical and transcatheter methods (including one small randomized trial and seven observational cohort studies; n = 1107 children), there was a higher incidence of residual shunt requiring reintervention after transcatheter closure (7 versus 0.3 percent) [21]. There was a nonsignificant trend towards more complications after surgical ligation; however, the overall number of complications was low. Length of stay after transcatheter closure was universally

shorter, while cost differences varied depending on the studies. A major limitation of this analysis is that a majority of studies included were conducted in the 1990s or earlier and only a small minority of patients (n = 20) underwent transcatheter closure using ADO devices, which are the most commonly used devices for transcatheter PDA closure in the modern era.

LONG-TERM MANAGEMENT

Follow-up

- **Follow-up after PDA closure** – There are limited data on the long-term outcomes of transcatheter occlusion of PDA. Our suggested approach is as follows:
  - Adults – In adults treated with transcatheter device occlusion, follow-up is recommended at least every five years assuming full closure is confirmed [1].
  - Children – In children, there are no guidelines for long-term follow-up after transcatheter occlusion. Many pediatric cardiologists discharge children from follow-up after six months to a year if there is no residual shunt, no pulmonary artery distortion or stenosis, and no aortic obstruction. Similar discharge from cardiology care is reasonable in cases of uncomplicated surgical ligation.
- **If PDA closure is deferred** – For patients in whom elective closure is deferred, follow-up evaluations should occur on a regular basis to monitor for signs of increased cardiac workload and/or pulmonary vascular changes. If these occur, PDA closure is indicated. (See 'Indications for closure' above.)

Antibiotic prophylaxis — Antibiotic prophylaxis for infective endocarditis is generally **not** necessary for patients with PDA, except in the following circumstances (see "Prevention of endocarditis: Antibiotic prophylaxis and other measures"):

- Patients with unrepaired PDA associated with other unrepaired cyanotic heart disease
- Patients who have undergone device closure or surgical ligation with prosthetic material or device during the first six months after the procedure
- Patients who have undergone device closure or surgical ligation if there is a residual defect adjacent to the site of repair

Sports participation — The 2015 scientific statement of the American Heart Association and American College of Cardiology provides competitive athletic participation guidelines for

patients with congenital heart disease (CHD), including PDA [59]. While we agree with the guidelines, we recommend that decisions regarding sports participation be made on an individual basis after discussion between the patient/guardians and treating cardiologist. Moreover, it must be emphasized that there are minimal data on sports participation in patients with CHD, and these guidelines are primarily based on a consensus of expert opinion:

- Patients with small untreated PDA can participate in all competitive sports if they have normal pulmonary artery pressure and normal heart size.
- Patients with untreated moderate or large PDA and persistent pulmonary hypertension may participate in class IA sports only (figure 2).
- Patients with untreated moderate or large PDA causing left ventricular enlargement should not participate in competitive sports until after surgical or interventional catheterization closure.
- Patients who have undergone catheter or surgical PDA closure can participate in all competitive sports if they have no evidence of pulmonary hypertension.
- Patients with residual pulmonary artery hypertension after PDA closure should be restricted from participation in competitive sports, with the possible exception of class IA sports (figure 2).

Physical activity and sports participation in patients with CHD are discussed in detail separately. (See "Physical activity and exercise in patients with congenital heart disease".)

SUMMARY AND RECOMMENDATIONS

- **Indications for closure** – Our approach to selecting patients for patent ductus arteriosus (PDA) closure is as follows (see 'Indications for closure' above):
  - **Moderate or large PDA** – For patients with moderate or large PDA associated with symptoms of left-to-right shunting, clinical evidence of left-sided cardiac overload (ie, left atrial or ventricular enlargement), or mild to moderate pulmonary arterial hypertension (PAH), we recommend PDA closure (**Grade 1B**).
  - **Prior episode of endocarditis** – For patients with a previous episode of infective endocarditis (IE), in the absence of severe PAH and regardless of the size of PDA, we suggest PDA closure (**Grade 2C**).

- **Small audible PDA** – For patients with small but audible PDAs even in the absence of a significant left-to-right shunt, we suggest PDA closure (**Grade 2C**). We believe the long-term benefit of closure (eg, prevention of endocarditis) outweighs the risk of intervention, especially in infants and children. An alternative approach is to defer PDA closure and routinely follow patients.

- **Unclear role of PDA closure for silent PDAs** – Silent PDAs are small defects (no audible murmur) that are detected incidentally by imaging studies performed for other indications. The management of these lesions is controversial. The decision to close a silent PDA should be individualized, based upon clinician, patient, and family preference after a discussion of the risks and theoretical benefits of the procedure. Silent PDAs do not have hemodynamic consequences, and, thus, the only impetus for closure is a theoretical increased risk of bacterial endocarditis.

- **Avoid PDA closure in patients with severe PAH** – Patients with severe, irreversible PAH and/or right-to-left shunting are generally not candidates for PDA closure. These patients have or are likely to develop Eisenmenger syndrome (PAH with right-to-left shunting and cyanosis) and may depend on the shunt for maintaining cardiac output. (See "Pulmonary hypertension in adults with congenital heart disease: General management and prognosis".)

- **Choice of closure intervention** – Once the decision is made for PDA closure, the choice of intervention (transcatheter occlusion versus surgical ligation) is based on the age and size of the patient and the experience and expertise of the clinician performing the procedure. The general approach is as follows (see 'Management approach' above and 'Therapeutic interventions' above):

  - **Preterm infants** – Preterm infants are discussed separately. (See "Patent ductus arteriosus in preterm infants: Management".)

  - **Term infants <6 kg** – For term infants <6 kg who have symptomatic PDAs, management consists of medical therapy for heart failure (eg, with diuretics and/or digoxin) until they are large enough to safely undergo transcatheter PDA occlusion. (See "Heart failure in children: Management", section on 'Pharmacologic therapy'.)

    If the infant fails medical therapy before that time, PDA closure may be required. Options for closure include surgical ligation or transcatheter closure in select cases if ductal anatomy is favorable. (See 'Term infants <6 kg' above.)

- **Infants >6 kg, children, adolescents, and adults** – In patients weighing >6 kg with indications for PDA closure, we suggest transcatheter PDA closure (picture 1 and picture 2A-B and image 1) rather than surgical ligation (**Grade 2B**). (See 'Infants and children >6 kg' above and 'Adolescents and adults' above.)

  The choice of occluder (coil versus device) depends upon the ductal morphology and size, and the size of the patient. (See 'Transcatheter closure' above.)

  Transcatheter PDA closure should be performed in centers with experienced interventional cardiologists. Surgical ligation is a reasonable alternative if experienced interventional services are not available. (See 'Surgical ligation' above.)

- **Follow-up** – Our suggested approach is as follows (see 'Follow-up' above):

  - **After PDA closure** – Children who have undergone PDA closure are typically discharged from pediatric cardiology follow-up care after 6 to 12 months if there is no residual shunt, no pulmonary artery distortion or stenosis, and no aortic obstruction. For adults, follow-up is recommended at least every five years following device occlusion, assuming full closure is confirmed.

  - **If PDA closure is deferred** – For patients in whom elective closure is deferred, follow-up evaluations should occur on a regular basis to monitor for signs of increased cardiac workload and/or pulmonary vascular changes. If these occur, PDA closure is indicated.

- **Prophylactic antibiotics** – Prophylaxis against IE is indicated for six months after transcatheter PDA closure, as discussed separately. (See "Prevention of endocarditis: Antibiotic prophylaxis and other measures".)

ACKNOWLEDGMENT

The editorial staff at UpToDate would like to acknowledge Thomas Graham Jr, MD, who contributed to an earlier version of this topic review.

Use of UpToDate is subject to the Terms of Use.

REFERENCES

1. Warnes CA, Williams RG, Bashore TM, et al. ACC/AHA 2008 Guidelines for the Management of Adults with Congenital Heart Disease: a report of the American College of Cardiology/American Heart Association Task Force on Practice Guidelines (writing committee to develop guidelines on the management of adults with congenital heart disease). Circulation 2008; 118:e714.
2. Campbell M. Natural history of persistent ductus arteriosus. Br Heart J 1968; 30:4.
3. Huggon IC, Qureshi SA. Is the prevention of infective endarteritis a valid reason for closure of the patent arterial duct? Eur Heart J 1997; 18:364.
4. Giroud JM, Jacobs JP. Evolution of strategies for management of the patent arterial duct. Cardiol Young 2007; 17 Suppl 2:68.
5. Lloyd TR, Beekman RH 3rd. Clinically silent patent ductus arteriosus. Am Heart J 1994; 127:1664.
6. Houston AB, Gnanapragasam JP, Lim MK, et al. Doppler ultrasound and the silent ductus arteriosus. Br Heart J 1991; 65:97.
7. Celebi A, Erdem A, Cokuğraş H, Ahunbay G. Infective endarteritis in a 2-month-old infant associated with silent patent ductus arteriosus. Anadolu Kardiyol Derg 2007; 7:325.
8. Parthenakis FI, Kanakaraki MK, Vardas PE. Images in cardiology: silent patent ductus arteriosus endarteritis. Heart 2000; 84:619.
9. Onji K, Matsuura W. Pulmonary endarteritis and subsequent pulmonary embolism associated with clinically silent patent ductus arteriosus. Intern Med 2007; 46:1663.
10. Ozkokeli M, Ates M, Uslu N, Akcar M. Pulmonary and aortic valve endocarditis in an adult patient with silent patent ductus arteriosus. Jpn Heart J 2004; 45:1057.
11. Fortescue EB, Lock JE, Galvin T, McElhinney DB. To close or not to close: the very small patent ductus arteriosus. Congenit Heart Dis 2010; 5:354.
12. Prieto LR, DeCamillo DM, Konrad DJ, et al. Comparison of cost and clinical outcome between transcatheter coil occlusion and surgical closure of isolated patent ductus arteriosus. Pediatrics 1998; 101:1020.
13. Thilén U, Aström-Olsson K. Does the risk of infective endarteritis justify routine patent ductus arteriosus closure? Eur Heart J 1997; 18:503.
14. Rigby ML. Closure of a large patent ductus arteriosus in adults: first do no harm. Heart 2007; 93:417.
15. Backes CH, Rivera BK, Bridge JA, et al. Percutaneous Patent Ductus Arteriosus (PDA) Closure During Infancy: A Meta-analysis. Pediatrics 2017; 139.

16. Backes CH, Kennedy KF, Locke M, et al. Transcatheter Occlusion of the Patent Ductus Arteriosus in 747 Infants <6 kg: Insights From the NCDR IMPACT Registry. JACC Cardiovasc Interv 2017; 10:1729.
17. Kang SL, Jivanji S, Mehta C, et al. Outcome after transcatheter occlusion of patent ductus arteriosus in infants less than 6 kg: A national study from United Kingdom and Ireland. Catheter Cardiovasc Interv 2017; 90:1135.
18. Nealon E, Rivera BK, Cua CL, et al. Follow-up after Percutaneous Patent Ductus Arteriosus Occlusion in Lower Weight Infants. J Pediatr 2019; 212:144.
19. Dutta S, Mihailovic A, Benson L, et al. Thoracoscopic ligation versus coil occlusion for patent ductus arteriosus: a matched cohort study of outcomes and cost. Surg Endosc 2008; 22:1643.
20. Feltes TF, Bacha E, Beekman RH 3rd, et al. Indications for cardiac catheterization and intervention in pediatric cardiac disease: a scientific statement from the American Heart Association. Circulation 2011; 123:2607.
21. Lam JY, Lopushinsky SR, Ma IW, et al. Treatment Options for Pediatric Patent Ductus Arteriosus: Systematic Review and Meta-analysis. Chest 2015; 148:784.
22. Yan C, Zhao S, Jiang S, et al. Transcatheter closure of patent ductus arteriosus with severe pulmonary arterial hypertension in adults. Heart 2007; 93:514.
23. Zhang DZ, Zhu XY, Lv B, et al. Trial occlusion to assess the risk of persistent pulmonary arterial hypertension after closure of a large patent ductus arteriosus in adolescents and adults with elevated pulmonary artery pressure. Circ Cardiovasc Interv 2014; 7:473.
24. Porstmann W, Wierny L, Warnke H. Closure of persistent ductus arteriosus without thoracotomy. Ger Med Mon 1967; 12:259.
25. Wierny L, Plass R, Porstmann W. Transluminal closure of patent ductus arteriosus: long-term results of 208 cases treated without thoracotomy. Cardiovasc Intervent Radiol 1986; 9:279.
26. Eerola A, Jokinen E, Boldt T, Pihkala J. The influence of percutaneous closure of patent ductus arteriosus on left ventricular size and function: a prospective study using two- and three-dimensional echocardiography and measurements of serum natriuretic peptides. J Am Coll Cardiol 2006; 47:1060.
27. El-Said HG, Bratincsak A, Foerster SR, et al. Safety of percutaneous patent ductus arteriosus closure: an unselected multicenter population experience. J Am Heart Assoc 2013; 2:e000424.

28. Rashkind WJ, Mullins CE, Hellenbrand WE, Tait MA. Nonsurgical closure of patent ductus arteriosus: clinical application of the Rashkind PDA Occluder System. Circulation 1987; 75:583.
29. Grifka RG, Vincent JA, Nihill MR, et al. Transcatheter patent ductus arteriosus closure in an infant using the Gianturco-Grifka Vascular Occlusion Device. Am J Cardiol 1996; 78:721.
30. Bridges ND, Perry SB, Parness I, et al. Transcatheter closure of a large patent ductus arteriosus with the clamshell septal umbrella. J Am Coll Cardiol 1991; 18:1297.
31. Pass RH, Hijazi Z, Hsu DT, et al. Multicenter USA Amplatzer patent ductus arteriosus occlusion device trial: initial and one-year results. J Am Coll Cardiol 2004; 44:513.
32. Thanopoulos BD, Hakim FA, Hiari A, et al. Further experience with transcatheter closure of the patent ductus arteriosus using the Amplatzer duct occluder. J Am Coll Cardiol 2000; 35:1016.
33. Bilkis AA, Alwi M, Hasri S, et al. The Amplatzer duct occluder: experience in 209 patients. J Am Coll Cardiol 2001; 37:258.
34. Thanopoulos BV, Eleftherakis N, Tzannos K, et al. Further experience with catheter closure of patent ductus arteriosus using the new Amplatzer duct occluder in children. Am J Cardiol 2010; 105:1005.
35. Patent Ductus Arteriosus Closure Devices Instructions for Use. http://professional.sjm.com/resources/ifu/sh/pda-closure (Accessed on February 07, 2014).
36. Patent Ductus Arteriosus (PDA) Closure Device. http://professional.sjm.com/products/sh/heart-occluders/pda-closure-devices (Accessed on February 07, 2014).
37. U.S. Food and Drug Administration Medical Devices. August 2013 PMA Approvals. Available at: http://www.fda.gov/MedicalDevices/ProductsandMedicalProcedures/DeviceApprovalsandClearances/PMAApprovals/ucm377425.htm (Accessed on December 09, 2015).
38. Gruenstein DH, Ebeid M, Radtke W, et al. Transcatheter closure of patent ductus arteriosus using the AMPLATZER™ duct occluder II (ADO II). Catheter Cardiovasc Interv 2017; 89:1118.
39. U.S. Food and Drug Administration summary of safety and effectiveness data. www.fda.gov/MedicalDevices/ProductsandMedicalProcedures/DeviceApprovalsandClearances/Recently-ApprovedDevices/ucm366245.htm (Accessed on January 20, 2014).
40. Moore JW, Greene J, Palomares S, et al. Results of the combined U.S. Multicenter Pivotal Study and the Continuing Access Study of the Nit-Occlud PDA device for percutaneous closure of patent ductus arteriosus. JACC Cardiovasc Interv 2014; 7:1430.
41. Delaney JW, Fletcher SE. Patent ductus arteriosus closure using the Amplatzer® vascular plug II for all anatomic variants. Catheter Cardiovasc Interv 2013; 81:820.

42. Backes CH, Giesinger RE, Rivera BK, et al. Percutaneous Closure of the Patent Ductus Arteriosus in Very Low Weight Infants: Considerations Following US Food and Drug Administration Approval of a Novel Device. J Pediatr 2019; 213:218.
43. Cambier PA, Kirby WC, Wortham DC, Moore JW. Percutaneous closure of the small (less than 2.5 mm) patent ductus arteriosus using coil embolization. Am J Cardiol 1992; 69:815.
44. Ebeid MR, Gaymes CH, Smith JC, et al. Gianturco-Grifka vascular occlusion device for closure of patent ductus arteriosus. Am J Cardiol 2001; 87:657.
45. Magee AG, Huggon IC, Seed PT, et al. Transcatheter coil occlusion of the arterial duct; results of the European Registry. Eur Heart J 2001; 22:1817.
46. Benson L, McLaughlin PR, Webb GD. The European experience with coil occlusion of PDA: strength in numbers. Eur Heart J 2001; 22:1768.
47. Celiker A, Aypar E, Karagöz T, et al. Transcatheter closure of patent ductus arteriosus with Nit-Occlud coils. Catheter Cardiovasc Interv 2005; 65:569.
48. Kumar RK, Krishnan MN, Venugopal K, et al. Bioptome-assisted simultaneous delivery of multiple coils for occlusion of the large patent ductus arteriosus. Catheter Cardiovasc Interv 2001; 54:95.
49. Hijazi ZM, Geggel RL. Transcatheter closure of large patent ductus arteriosus (> or = 4 mm) with multiple Gianturco coils: immediate and mid-term results. Heart 1996; 76:536.
50. Galal MO. Advantages and disadvantages of coils for transcatheter closure of patent ductus arteriosus. J Interv Cardiol 2003; 16:157.
51. Mavroudis C, Backer CL. Pediatric Cardiac Surgery, 3rd ed, Mosby-Year Book Inc, Philadelphia 2003. p.875.
52. Bensky AS, Raines KH, Hines MH. Late follow-up after thoracoscopic ductal ligation. Am J Cardiol 2000; 86:360.
53. Nezafati MH, Soltani G, Kahrom M. Esophageal stethoscope: an old tool with a new role, detection of residual flow during video-assisted thoracoscopic patent ductus arteriosus closure. J Pediatr Surg 2010; 45:2141.
54. Vanamo K, Berg E, Kokki H, Tikanoja T. Video-assisted thoracoscopic versus open surgery for persistent ductus arteriosus. J Pediatr Surg 2006; 41:1226.
55. Chen H, Weng G, Chen Z, et al. Comparison of posterolateral thoracotomy and video-assisted thoracoscopic clipping for the treatment of patent ductus arteriosus in neonates and infants. Pediatr Cardiol 2011; 32:386.
56. Nezafati MH, Soltani G, Vedadian A. Video-assisted ductal closure with new modifications: minimally invasive, maximally effective, 1,300 cases. Ann Thorac Surg 2007; 84:1343.

57. Omari BO, Shapiro S, Ginzton L, et al. Closure of short, wide patent ductus arteriosus with cardiopulmonary bypass and balloon occlusion. Ann Thorac Surg 1998; 66:277.
58. Stankowski T, Aboul-Hassan SS, Marczak J, et al. Minimally invasive thoracoscopic closure versus thoracotomy in children with patent ductus arteriosus. J Surg Res 2017; 208:1.
59. Van Hare GF, Ackerman MJ, Evangelista JA, et al. Eligibility and Disqualification Recommendations for Competitive Athletes With Cardiovascular Abnormalities: Task Force 4: Congenital Heart Disease: A Scientific Statement From the American Heart Association and American College of Cardiology. Circulation 2015; 132:e281.

Topic 5771 Version 20.0

GRAPHICS

Patent ductus arteriosus

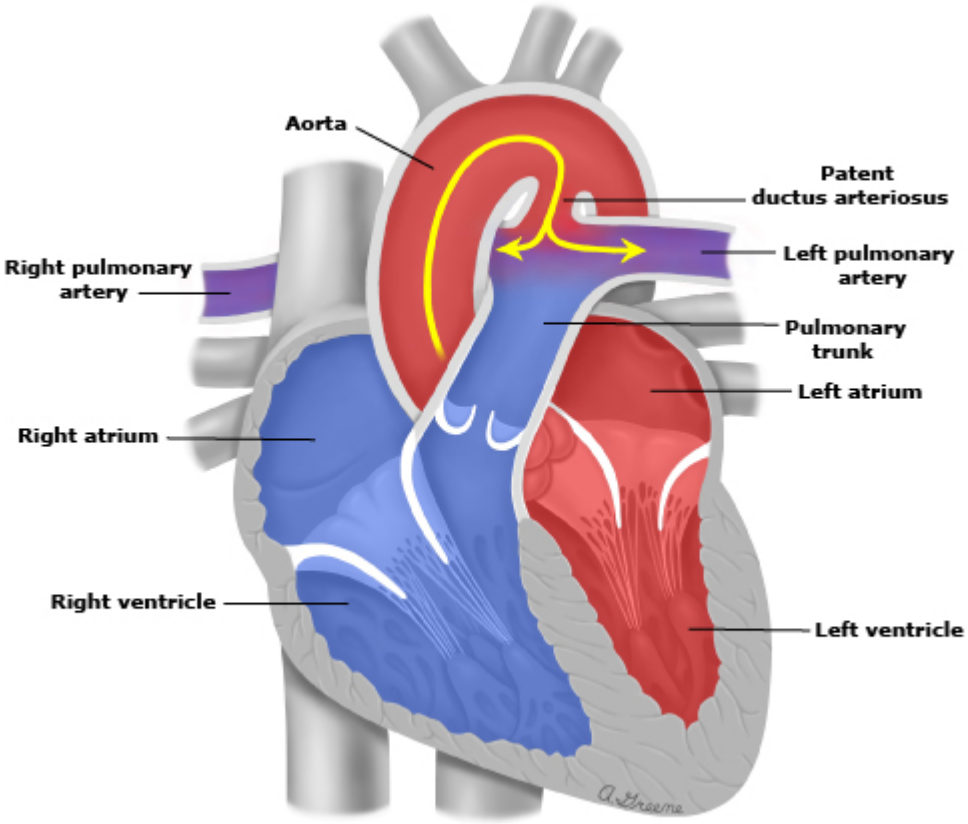

Graphic 65828 Version 2.0

Angiographic images of percutaneous closure of a patent ductus arteriosus

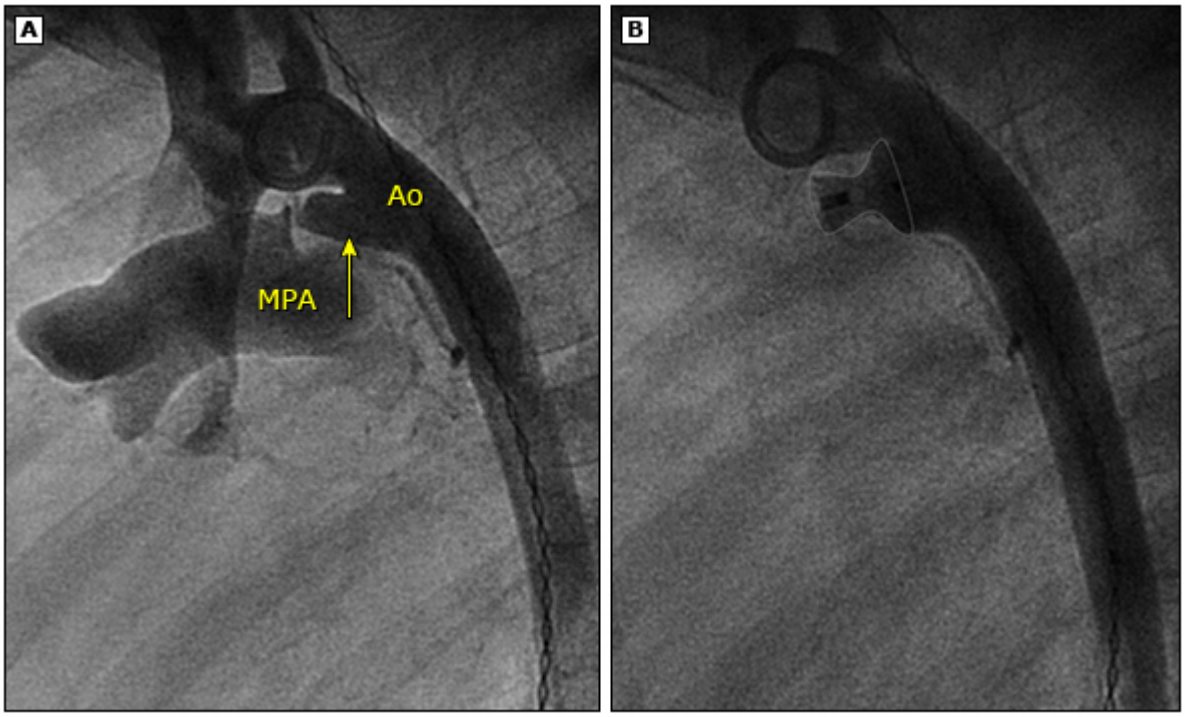

(A) Angiogram demonstrating a PDA (arrow) with left-to-right shunt from the aorta (Ao) into the main pulmonary artery (MPA).

(B) Repeat angiogram after placement of an Amplatzer ductal occluder device (outlined). There is residual flow into the device, but no residual shunt into the main pulmonary artery. Flow into the device will resolve with reversal of heparinization, and ultimately the device will be completely endothelialized.

PDA: patent ductus arteriosus.

Graphic 93748 Version 1.0

Gianturco coils used to close patent ductus arteriosus

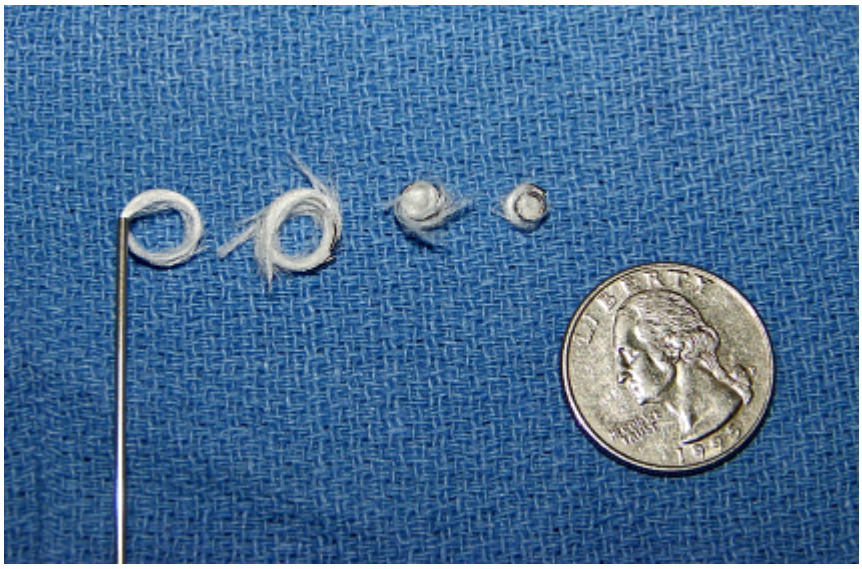

Gianturco coils have been utilized for percutaneous occlusion of patent arteriosus ductus. Coils come in a variety of sizes. They are usually made of stainless steel and contain fibers to increase their thrombogenicity.

Courtesy of Kevin Hill, MD.

Graphic 69599 Version 4.0

Amplatzer ductal occluder device

Courtesy of Kevin Hill, MD.

Graphic 73178 Version 4.0

The AMPLATZER Duct Occluder II device

AMPLATZER and St. Jude Medical are trademarks of St. Jude Medical, Inc. or its related companies. Reprinted with permission of St. Jude Medical, Copyright © 2014. All rights reserved.

Graphic 93728 Version 1.0

Classification of sports based on peak static and dynamic components during competition

Increasing static component	A. Low (<50%)	B. Moderate (50 to 75%)	C. High (>75%)
III. High (>30%)	Bobsledding/luge Field events (throwing) Gymnastics*¶ Martial arts Rock climbing Sailing Water skiing*¶ Weight lifting*¶ Windsurfing*¶	Bodybuilding*¶ Downhill skiing Skateboarding*¶ Snowboarding*¶ Wrestling*	Boxing Canoeing Kayaking Cycling*¶ Decathlon Rowing Speed skating Triathlon*¶
II. Moderate (10 to 20%)	Archery Auto racing*¶ Diving*¶ Equestrian*¶ Motorcycling*¶	American football* Field events (jumping) Figure skating Rodeoing*¶ Rugby Running (sprint) Surfing Synchronized swimming¶ "Ultra" racing	Basketball* Ice hockey* Cross-country skiing (skating technique) Lacrosse* Running (middle distance) Swimming Team handball Tennis
I. Low (<10%)	Bowling Cricket Curling Golf Riflery Yoga	Baseball/softball Fencing Table tennis Volleyball	Badminton Cross-crountry skiing (classic technique) Field hockey* Orienteering Race walking Racquetball/squash Running (long distance) Soccer*

Increasing dynamic component →

This classification is based on peak static and dynamic components achieved during competition; however, higher values may be reached during training. The increasing dynamic component is defined in terms of the estimated percentage of maximal oxygen uptake (VO_2max) achieved and results in an increasing cardiac output. The increasing static component is related to the estimated percentage of maximal voluntary contraction reached and results in an increasing blood pressure load. The lowest total cardiovascular demands (cardiac output and blood pressure) are shown in the palest color, with increasing dynamic load depicted by increasing blue intensity and increasing static load by increasing red intensity. Note the graded transition between categories, which should be individualized on the basis of player position and style of play.

---

* Danger of bodily collision (refer to UpToDate content regarding sports according to risk of impact and educational background).

¶ Increased risk if syncope occurs.

Reproduced from: Levine BD, Baggish AL, Kovacs RJ. Eligibility and disqualification recommendations for competitive athletes with cardiovascular abnormalities: Task force 1: Classification of sports: Dynamic, static, and impact: A scientific statement from the American Heart Association and American College of Cardiology. J Am Coll Cardiol 2015; 66:2350. Illustration used with the permission of Elsevier Inc. All rights reserved.

Graphic 105651 Version 9.0

Contributor Disclosures

Thomas Doyle, MD Equity Ownership/Stock Options: Influent Medical, LLC [Patent ductus arteriosus]. All of the relevant financial relationships listed have been mitigated. **Ann Kavanaugh-McHugh, MD** No relevant financial relationship(s) with ineligible companies to disclose. **Jonathan Soslow, MD** Consultant/Advisory Boards: PepGen [Duchenne muscular dystrophy]; Sarepta [Becker muscular dystrophy]. All of the relevant financial relationships listed have been mitigated. **Kevin Hill, MD** No relevant financial relationship(s) with ineligible companies to disclose. **John K Triedman, MD** Consultant/Advisory Boards: Biosense Webster and Sentiar [Supraventricular and ventricular topics]. All of the relevant financial relationships listed have been mitigated. **Heidi M Connolly, MD, FACC, FASE** No relevant financial relationship(s) with ineligible companies to disclose. **Carrie Armsby, MD, MPH** No relevant financial relationship(s) with ineligible companies to disclose.

Contributor disclosures are reviewed for conflicts of interest by the editorial group. When found, these are addressed by vetting through a multi-level review process, and through requirements for references to be provided to support the content. Appropriately referenced content is required of all authors and must conform to UpToDate standards of evidence.

Conflict of interest policy

→